

Evaluation of computed radiographic protruded liver length (RLLP) to radiographic liver length (RLL) ratio in dogs

Bharti A^{1*}, Pradeep Kumar¹, Chaudhary S¹, Karir SR¹, Singh S¹, Mohammed N²

¹Department of Veterinary Surgery and Radiology

²Department of Veterinary Medicine

Post Graduate Institute of Veterinary Education and Research (PGIVER), Jaipur, Rajasthan, India

Corresponding author: anilbharti34@gmail.com

Received on: 17/09/2025

Accepted on: 25/12/2025

Published on: 30/12/2025

ABSTRACT

Aim: Main purpose of the study was to evaluate ratio of computed radiographic protruded liver length (RLLP) to radiographic liver length (RLL) for setting up a quantitative index in clinically healthy dogs.

Materials and Methods: A total 104 dogs were examined through computed radiography. One year and above aged dogs of 10 breeds of different body weights were included in the study. Computed radiography was done for right lateral (RL) views in all dogs. The ratio was evaluated according to age, sex, body weight, breed and neutering status.

Results: Breeds-wise measurements of ratio of radiographic protruded liver length (RLLP) to radiographic liver length (RLL) were 0.02 ± 0.01 , 0.01 ± 0.01 , 0.02 ± 0.01 , 0.02 ± 0.01 , 0.02 ± 0.01 , 0.14 ± 0.01 , 0.10 ± 0.03 , 0.05 ± 0.04 , 0.11 ± 0.01 , and 0.10 ± 0.01 as mean \pm S.E. in groups of GSD, BSD, Husky, Doberman, GR, Lab, IM, Pom, Pug, and Beagle respectively. Age-wise measurements of ratio of radiographic protruded liver length (RLLP) to the radiographic liver length (RLL) were 0.05 ± 0.01 , 0.11 ± 0.02 , 0.09 ± 0.02 and 0.09 ± 0.04 in 1-3 year, 3.1-6 year, 6.1-9 year and 9.1-12 year of age groups, respectively. Body weight-wise measurements of the ratio of radiographic protruded liver length (RLLP) to radiographic liver length (RLL) were 0.09 ± 0.01 , 0.04 ± 0.01 and 0.14 ± 0.05 in groups of 10-20 Kg, 21-30 Kg and 31-40 Kg respectively. Sex-wise measurements of the ratio of RLLP/RLL were measured in male 0.08 ± 0.01 and female 0.07 ± 0.01 . Neutering status wise measurements of the ratio of RLLP/RLL were 0.06 ± 0.01 in intact dogs and 0.10 ± 0.02 in neutered (spayed/castrated) dogs.

Conclusion: It was concluded that the Radiographic morphometry of the liver varies according to signalment characteristics in dogs. Ratio of radiographic protruded liver length (RLLP) to radiographic liver length (RLL) is set as a novel quantitative index of radiographic liver size in dogs.

Keywords: Radiographic protruded liver length, radiographic liver length, radiographic measurements.

How to cite this article: Bharti A, Pradeep Kumar, Chaudhary S, Karir SR and Mohammed N (2025). Evaluation of computed radiographic protruded liver length (RLLP) to radiographic liver length (RLL) ratio in dogs. J. Agri. Res. Adv., 07(04): 43-47.

Introduction

Liver is the largest gland and has a wide array of metabolic functions as synthesis and secretion of bile acids, plasma protein, lipid and lipoprotein, vitamin storage, glucose homeostasis, biotransformation, detoxification and excretion of a vast number of endogenous and exogenous compounds (Nelson *et al.*, 1996 and Bermingham *et al.*, 2001). Liver failure does not occur until 20-30 per cent of the liver's functional capability is intact in animals (Bexfield and Watson, 2006). Dogs primarily present with parenchymal pathologies such as hepatitis (Watson, 2004 and Center, 2009).

The estimated frequency of canine hepatitis depends on the investigated population and accounts for 1% 2% of clinic referral population (Poldervaart *et al.*, 2009) and up to 12% in a general population (Watson *et al.*, 2010). Liver affections i.e. hepatomegaly, microhepatita, liver cyst, abscess, neoplasia and mineralisation of liver etc. are commonly observed (Negasee, 2021). Causes of reduced liver size include hepatic fibrosis, cirrhosis, congenital atrophy, emaciation, and artifacts (Suter, 1982).

Measuring the size of the liver can assist in screening for liver disease and in making differential diagnosis (Cha *et al.*, 2018). There is a wide variation in liver size according to age and breed of the dog. Changes in hepatic size are frequently used as indicators of liver disease (Wrigley, 1985; Choi *et al.*, 2013; Cockett, 1986; Lee and Leowijuk, 1982; Penninck and Berry, 1997). In veterinary practice, liver size is assessed

Copyright: Bharti et al. Open Access. This article is distributed under the terms of the Creative Commons Attribution 4.0 International License (<http://creativecommons.org/licenses/by/4.0/>), which permits unrestricted use, distribution, and reproduction in any medium, provided you give appropriate credit to the original author(s) and the source, provide a link to the Creative Commons license, and indicate if changes were made.

radiographically by examining caudal liver margins' position relative to costal arch and stomach, although breed differences limit accuracy (Bree and Sackx, 1987). Radiography and ultrasonography are complementary methods for diagnosing abdominal diseases (O'Brien, 1978). Survey abdominal radiographs can be used to assess morphologic abnormalities in the liver's size, shape, density (mineralization/radiolucency), position and presence of abdominal effusion (Konde and Pugh, 1996).

In dogs with generalized liver enlargement, the stomach axis is caudally shifted and caudoventral liver margin is blunted or rounded, extending past the costal arch (Wrigley, 1985; Suter, 1982; Partington and Biller, 1995 and Larson, 2018). The caudate lobe is primarily located on the right side, which may facilitate improved visualization of the liver when the animal is positioned in right lateral recumbency (Lee and Leowijuk, 1982).

The Ratio of radiographic protruded liver length (RLLP) to radiographic liver length (RLL) was intricated by quantifying liver size in dogs. The aim of the current study was to evaluate the normal range of ratio of radiographic protruded liver length (RLLP) to radiographic liver length (RLL) values in clinically healthy dogs.

Materials and Methods

It was included 104 dogs from ten different breeds that encountered thoracoabdominal computed radiography. The study included dogs with good overall health, no history of chronic illnesses or systemic disorders brought to the hospital for a general check-up. The study comprised of dogs aged one year or older and of various body weights.

Radiographs were taken with a 500 mA X-Ray machine (EP-CORSA 40kw/Epsilon Health Care Solutions Pvt. Ltd.) at a focal film distance of 90cm. for all dogs, Right lateral radiographs were taken, examined and interpreted. Radiographic liver length (cm) was measured as the axis length from the ventral border of caudal vena cava to the apex of hepatic caudo-ventral border. Protruded length of liver (cm) was measured through drawing a line from curve of last rib of coastal arch to apex (Caudoventral tip of liver/tip of the protruded liver part). Both measurements were recorded using a computed radiography CR system and the ratio of RLLP to RLL was calculated.

The data obtained were subjected to analysis by independent sample t test and one-way analysis of variance (ANOVA) technique (Snedecor and Cochran, 2004) using the statistical package SPSS software version 21.

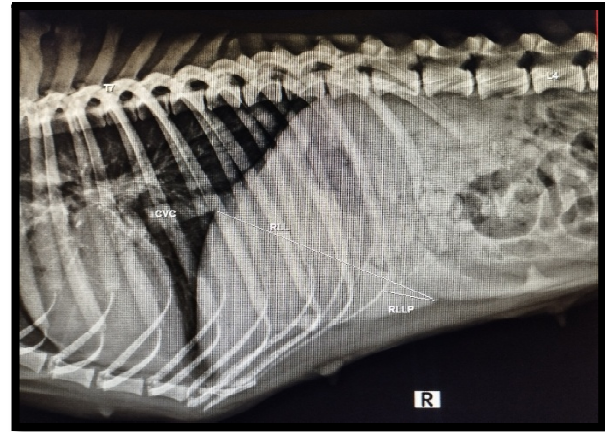


Fig 1. Image showing radiographic measurement of RLL and RLLP

Results and Discussion

The ratio of radiographic protruded liver length to radiographic liver length was measured in this study at 0.02 ± 0.01 , 0.01 ± 0.01 , 0.02 ± 0.01 , 0.02 ± 0.01 , 0.02 ± 0.01 , 0.14 ± 0.01 , 0.10 ± 0.03 , 0.05 ± 0.04 , 0.11 ± 0.01 , and 0.10 ± 0.01 in GSD, BSD, Siberian husky, Doberman, Golden retriever, Labrador retriever, Indian mongrel, Pomeranian, Pug and Beagle respectively. There was no significant difference ($p < 0.05$) in the ratio of radiographically protruded liver length to total radiographic liver length among the GSD, BSD, Siberian husky, Doberman, Golden retriever, Labrador retriever, Indian mongrel, Pomeranian, Pug and Beagle groups. The LAB group recorded the highest value for the ratio of protruded liver length to total liver length, while the BSD group had the lowest value. Similarly, Choi *et al.* (2013) compared Pekingese dogs to other breeds revealed that Pekingese have a smaller normal radiographic liver size. However, Thrall and Robertson (2015) showed liver size decreased in dogs with a deep thoracic cavity, as liver is positioned more completely within the costal arch.

The ratio of radiographic protruded liver length to radiographic liver length was measured in this study at 0.05 ± 0.01 , 0.11 ± 0.02 , 0.09 ± 0.02 and 0.09 ± 0.04 in 1-3 year, 3.1-6 year, 6.1-9 year and 9.1-12 year of age groups, respectively.

Table 1. Breed wise Mean ± S.E. values of RLLP: RLL ratio

Ratio	Breeds								
	GSD	BSD	HUSKY	DOBERMENN	GR	LAB	IM	POM	PUG
RLLP/RLL	0.02 ^{ab±}	0.01 ^{a±}	0.02 ^{ab±}	0.02 ^{ab±}	0.02 ^{ab±}	0.14 ^{d±}	0.10 ^{bcd±}	0.05 ^{abc±}	0.11 ^{cd±}
	0.01	0.01	0.01	0.01	0.01	0.01	0.03	0.04	0.01

Mean superscripted in a column differ significantly (p<0.05).

No significant difference (p<0.05) was observed in the mean value of the ratio of radiographic protruded liver length to radiographic liver length between these groups. Karir *et al.* (2024) also reported radiographic liver length (RLL) values across various age groups which were consistent with the present study. Likewise, Nyland *et al.* (2015) observed comparable results with variations in liver size during radiographic evaluations were largely influenced by individual anatomical differences rather than distinct group characteristics.

The ratio of radiographic protruded liver length to radiographic liver length was measured in this study at 0.09±0.01, 0.04±0.01 and 0.14±0.05 in groups of 10-20 Kg, 21-30 Kg and 31-40 Kg respectively. The group of dogs with 31-40kg weight reported the highest mean value of the ratio of radiographic protruded liver length to radiographic liver length, rather than this group also showed a significant difference (p<0.05) with the 10-20kg and 21-30kg body weight group. Karir *et al.* (2024) also reported various ratios to radiographic measurement of liver in dogs. Likewise, Lamb (2016) revealed greater visible liver protrusion in lateral radiographs in deep-chested dog breeds. In present study, it was observed significant variations in liver protrusion ratio among different weight groups with larger dogs exhibiting higher ratios of liver protrusion. However, Kealy and McAllister (2010) noted less liver protrusion in deep-chested dogs, even when their overall body weight is significantly higher. The observation presented a striking contrast to the findings of the present study.

Table 2. Age wise Mean ± S.E. values of RLLP:RLL ratio

Ratio	Age			
	1-3 yr	3.1-6 yr	6.1-9 yr	9.1-12 yr
RLLP/RLL	0.05 ^{a±} 0.01	0.11 ^{a±} 0.02	0.09 ^{a±} 0.02	0.09 ^{a±} 0.04

Table 3. Body weight wise Mean±S.E. values of RLLP:RLL ratio

Ratio	Body weight (Kg)		
	10-20kg	21-30kg	31-40kg
RLLP/RLL	0.09 ^{a±} 0.01	0.04 ^{a±} 0.01	0.14 ^{b±} 0.05

Table 4. Sex wise Mean ± S.E. values of RLLP:RLL ratio

Ratio	Sex	
	Male	Female
RLLP/RLL	0.08 ^{a±} 0.01	0.07 ^{a±} 0.01

Table 5. Status of neutering wise Mean±S.E. values of RLLP: RLL ratio

Ratio	Sex	
	Intact	Neutered
RLLP/RLL	0.06 ^{a±} 0.01	0.10 ^{a±} 0.02

Mean superscripted in a column differ significantly (p<0.05).

The ratio of radiographic protruded liver length to radiographic liver length was measured in male 0.08±0.01 and female 0.07±0.01. Any significant difference was absent (p<0.05) between these groups. Similarly, Schwarz and Johnson (2019) reported sex of dog had no significant impact on hepatic measurements. In contrast, Barr and Gaschen (2018) advocated differences in liver parameters.

In the present study, the ratio of radiographic protruded liver length (RLLP) to radiographic liver length (RLL) was calculated 0.06±0.01 in intact dogs and 0.10±0.02 in neutered (spayed/castrated) dogs, according to the dogs' neutering status. There was a lack of any significant difference (p<0.05) between these two groups. Similarly, Nyland *et al.* (2015) and Schwarz and Johnson (2019) reported a link between neutering and an increased protrusion of the liver. Furthermore, the current results were in agreement with the findings of Thrall (2020) that favoured variation of radiographic liver length according to the dog's neutering status. The study introduced an innovative metric that compared length of protruded portion of the liver to overall length, both of which were measured through radiographic imaging techniques. The ratio served as a valuable indicator for assessing liver conditions.

Conclusions

It was concluded that radiographic morphometry of the liver varies according to signalment characteristics in dogs. Ratio of radiographic protruded liver length (RLLP) to radiographic

liver length (RLL) is set as a novel quantitative index of radiographic liver size in dogs.

References

- An G, Yoon H, Yu J, Bang S, Lee Y, Jeon S, Jung J, Chang J and Chang D (2019). Evaluation of the radiographic liver length/11th thoracic vertebral length ratio as a method for quantifying liver size in cats. *Veterinary radiology and ultrasound: the official journal of the American College of Veterinary Radiology and the International Veterinary Radiology Association*, 60(6): 640-647.
- Bexfield N and Watson P (2006). Diagnosis of canine liver disease. In *practice*, 28(8): 444-453.
- Bhargavi S, Kannan AT, Ramesh G, Sumathi D and Prasad AA (2018). Radiographic evaluation of the caudal vena cava and descending aorta in indigenous dog breeds of Tamil Nadu. *J. Entomology and Zoology Studies*, 6(6): 159-162.
- Bree HV and Sackx A (1987). Evaluation of radiographic liver size in twenty-seven normal deep-chested dogs. *Journal of Small Animal Practice*, 28: 693-703.
- Buchanan JW and Bücheler J (1995). Vertebral scale system to measure canine heart size in radiographs. *Journal of the American Veterinary Medical Association*, 206(2): 194-199.
- Center SA (2009). Diseases of the gallbladder and biliary tree. *The Veterinary Clinics of North America. Small Animal Practice*, 39(3): 543-598.
- Cha A, Park S, Kim C, Yoon S, Lee D, Kim D, Chang DW and Choi J (2018). Effect of radiographic technique on assessment of liver size in Beagles. *American journal of veterinary research*, 79(11): 1133-1139.
- Choi J, Keh S, Kim H, Kim J and Yoon J (2013). Radiographic liver size in Pekingese dogs versus other dog breeds. *Veterinary radiology and ultrasound: the official journal of the American College of Veterinary Radiology and the International Veterinary Radiology Association*, 54(2): 103-106.
- Cockett PA (1986). Radiographic anatomy of the canine liver: simple measurements determined from the lateral radiograph. *J. Small Anim. Practice*, 27(9): 577-589.
- Karir SR, Kumar P, Pandey N, Singh S and Mohammed N (2024). Evaluation of radiographic liver length to 11th thoracic vertebral length ratio in deep chested dog. *J. Vet. Res. Adv.*, 06(01): 63-67.
- Konde LJ and Pugh CR (1996). Radiography and sonography of the digestive system. In: *Handbook of Small Animal Gastroenterology*. 1st Edn. Tams, T.R. (Eds.) W. B. Saunders, Philadelphia, USA. pp. 75-135.
- Larson MM (2013). The liver and spleen. In: Thrall DE, ed. *Text book of veterinary diagnostic radiology*, 6th ed. St Louis: Elsevier, pp. 679-684.
- Lee R and Leowijuk C (1982). Normal parameters in abdominal radiology of the dog and cat. *Journal of Small Animal Practice*, 23(5): 251-269.
- Negasee KA (2021). Hepatic diseases in canine and feline: A review. *Veterinary Medicine Open Journal*, 6(1): 22-31.
- O'Brien TR (1978). *Radiographic Diagnosis of Abdominal Diseases in the Dog and Cat*, W.B. Saunders and Company, Philadelphia, pp. 396-480. Parey and Paul, 3rd Ed., Verlag, Berlin, Hamburg.
- Partington BP and Biller DS (1995). Hepatic imaging with radiology and ultrasound. *The Veterinary clinics of North America. Small animal practice*, 25(2): 305-335.
- Penninck D and Berry C (1997). Liver imaging in the cat. *Semin Vet Med Surg Small Anim.* 12: 10-21.
- Poldervaart JH, Favier RP, Penning LC, van den Ingh TS and Rothuizen J (2009). Primary hepatitis in dogs: a retrospective review (2002-2006). *Journal of Veterinary Internal Medicine*, 23(1): 72-80.
- Snedecor GW and Cochran WG (1989). *Statistical methods*, 8thEdn. Ames: Iowa State Univ. Press Iowa, 54: 71-82.
- Stahl WM (1965). Effect of mannitol on the kidney: changes in intrarenal hemodynamics. *New England Journal of Medicine*, 272(8): 381-386.
- Suter PF (1982). Radiographic diagnosis of liver disease in dogs and cats. *The Veterinary clinics of North America: Small Animal Practice*, 12(2): 153-173.
- Watson PJ (2004). Chronic hepatitis in dogs: a review of current understanding of the aetiology, progression and treatment.

Veterinary Journal (London, England), 167(3): 228-241.
Watson PJ, Roulois AJ, Scase TJ, Irvine R and Herrtage ME (2010). Prevalence of hepatic lesions at post-mortem examination in dogs and association with pancreatitis. The Journal of Small Animal Practice, 51(11): 566-572.

Wrigley RH (1985). Radiographic and ultrasonographic diagnosis of liver diseases in dogs and cats. The Veterinary Clinics of North America: Small Animal Practice, 15(1): 21-38.
